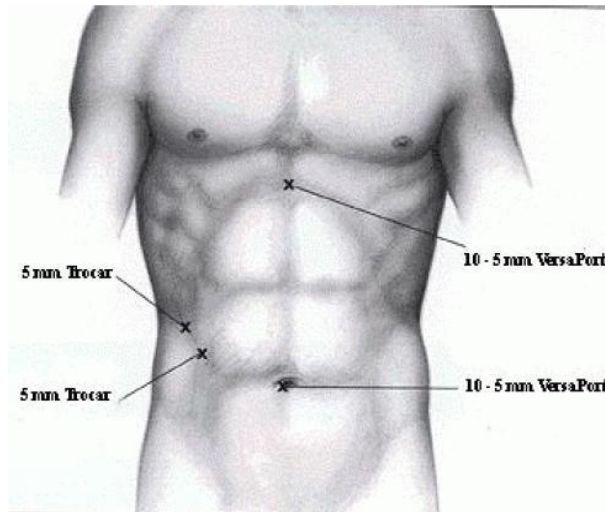
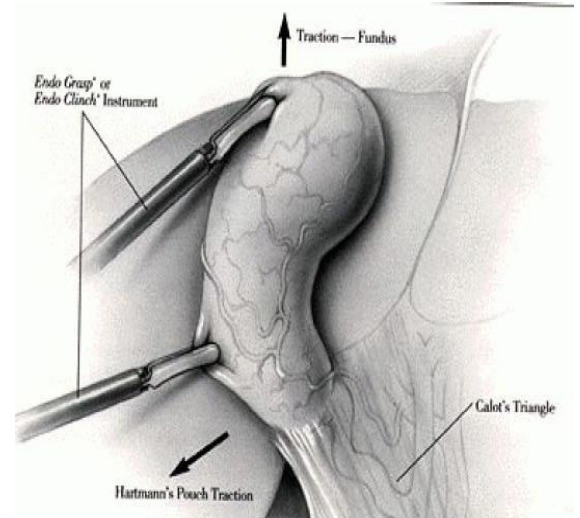


# Appendix I Laparoscopic Cholecystectomy Procedures

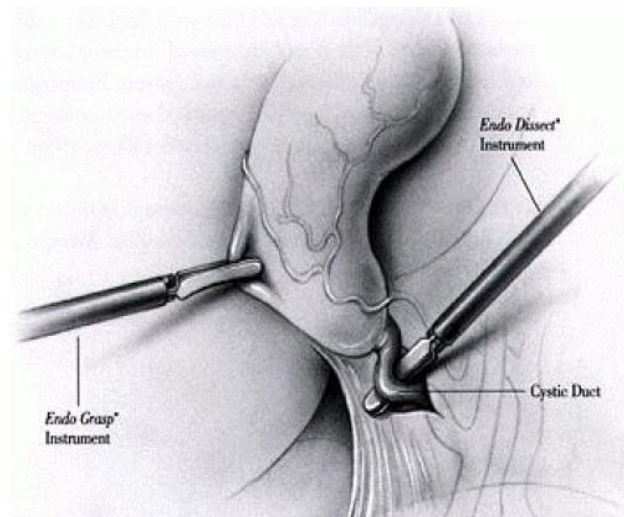
1. Determination of Port on patient body



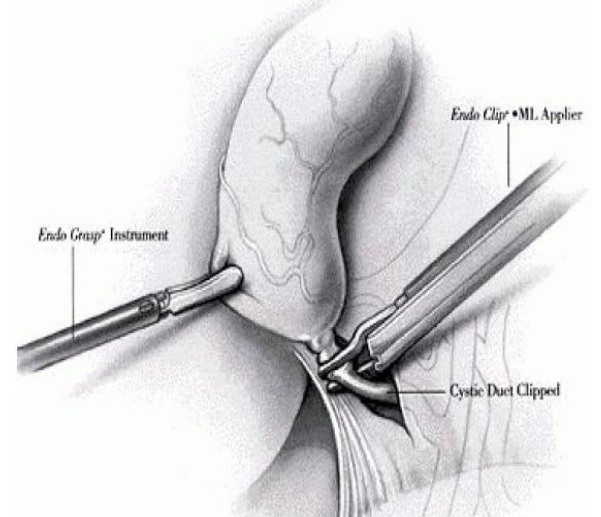
2. Use Grasper to expose the triangle of Callot



3. Searching for Cystic Duct

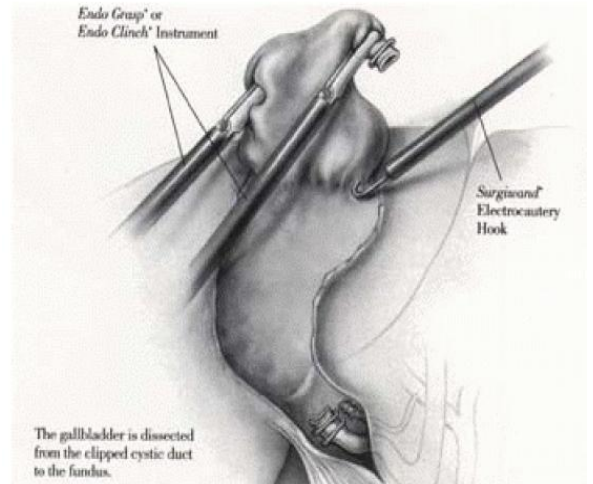
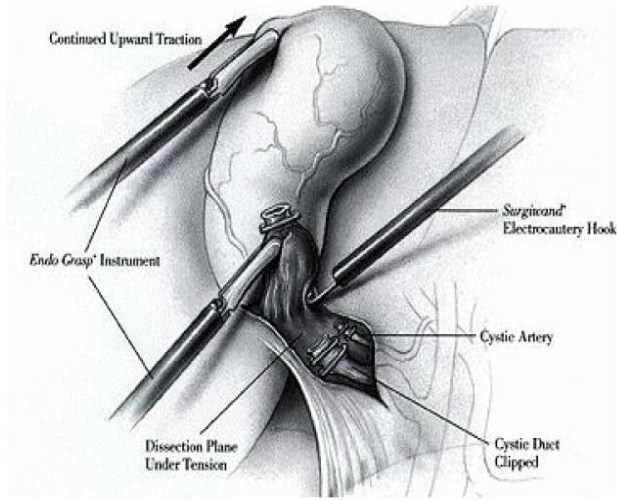


4. Clipping of Cystic Duct



5. Cystic artery is divided by hook scissors

6. The gallbladder is dissected from the clipped cystic duct to the fundus



## 7. Dissection of Gallbladder from Liver Bed

